

PATIENT
Chomper Williams

SPECIES
Feline

BREED
DSH

SEX
Male Neutered

AGE
7 years

WEIGHT
10.8lbs

INTERPRETED BY
Maggie Machen
Lamy, DVM, DACVIM
(Cardiology)

IMAGING PERFORMED BY
Jenna Walsh, CVT

HOSPITAL NAME
West Salem Animal
Clinic

REFERRING VET
Dr. Sirianni

INVOICE
30611

DATE
5/4/23

PRESENTING CLINICAL SIGNS

History: Initially seen for labored breathing; asthma suspected and Prednisone instituted. Returned a few days later after further decline and found pleural effusion. Sedated with Torb.

RADIOGRAPHIC FINDINGS *NOTE: Images submitted for supplemental cardiac information only.
 (5/1/23): Mild cardiomegaly. No obvious evidence of CHF.
 (5/4/23): Pleural effusion noted.

ELECTROCARDIOGRAPHIC FINDINGS *Note: Single lead ECGs are evaluated as a rhythm strip. Morphology/MEA cannot be definitively commented on.
 A single lead ECG is available; 50mm/s, 20mm/mV. The average heart rate is 150bpm with a largely regular rhythm. The rhythm is sinus in origin, with a p for every QRS complex and vice versa. The P and QRS morphologies are positive. No ectopic beats, pauses or dysrhythmias observed.
 ECG diagnosis: Normal sinus rhythm.

ECHOCARDIOGRAM FINDINGS

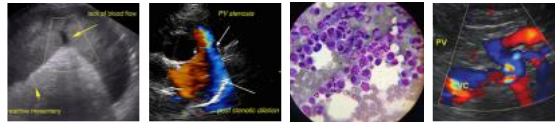
2D, m-mode, color flow and doppler imaging is available. The left ventricular wall is normal in dimension. There is a mildly hyperechoic endocardium consistent with mild fibrosis. The endocardium also appears mildly remodeled. The papillary muscles are normal in size and hyperechoic. The left atrium is normal in size. The right atrium is normal in size. The right ventricle appears normal. The mitral valve is normal in structure and mobility. No obvious valve regurgitation. Blood flow through both the LVOT and RVOT is normal in velocity. Small volume pleural and trivial pericardial effusion seen. No obvious cardiac tumors. Ascites seen on subcostal views.

CARDIAC CHART

FELINE CARDIAC PARAMETERS	BODY WEIGHT (kg)	HR (BPM)	IVSd (cm) <small>(Moise, Pipers)</small>	LVIDd (cm) <small>(Moise, Pipers)</small>	LWVd (cm) <small>(Moise, Pipers)</small>	FS (%)	EF (%)
NORMAL PARAMETER	-----	150-240	0.35-0.55	<2 (mean 1.5)	3.5-0.55	35-67	80-100
PATIENT	4.9	NM	0.52	1.5	0.45	50	84
FELINE CARDIAC PARAMETERS	LA/AO <small>(Boon)</small>	LA/AO HEART BASE (Swe) <small>(Abbott)</small>	LA 2D short axis Base view (cm) <small>(Abbott)</small>		LVOT VEL <small>(m/s)</small>	RVOT VEL <small>(m/s)</small>	E max <small>(m/s)</small>
NORMAL	<1.5	<1.3	<1.2		<1.6	<1.3	<0.9
PATIENT	1.1	1.1	1.1		0.9	0.8	NM
<p>*Note: All measurements based upon multi-modal images and methods. An average value is reported. Adapted from June Boon, Veterinary Echocardiography, 1998 Abbott J & MacLean H JVIM 2006;20: 111-119, Moise et al. Am J Vet Res 47:1476, 1986. Pipers et al. Am J Vet Res 40:882, 1979.</p>							

INTERPRETATION OF THE FINDINGS & FURTHER RECOMMENDATIONS

Overtly normal cardiac structure and function. The LV wall thickness is normal, and there is no evidence of elevated left atrial pressure or underlying pathology at this time. There is mild remodeling and fibrosis of the left ventricular wall, which is considered likely a normal age-related finding. The ECG is unremarkable with a normal sinus rhythm.



PATIENT

Chomper Williams

SPECIES

Feline

BREED

DSH

SEX

Male Neutered

AGE

7 years

WEIGHT

10.8lbs

INTERPRETED BY

Maggie Machen Lamy, DVM, DACVIM (Cardiology)

IMAGING PERFORMED BY

Jenna Walsh, CVT

HOSPITAL NAME

West Salem Animal Clinic

REFERRING VET

Dr. Sirianni

INVOICE

30611

DATE

5/4/23

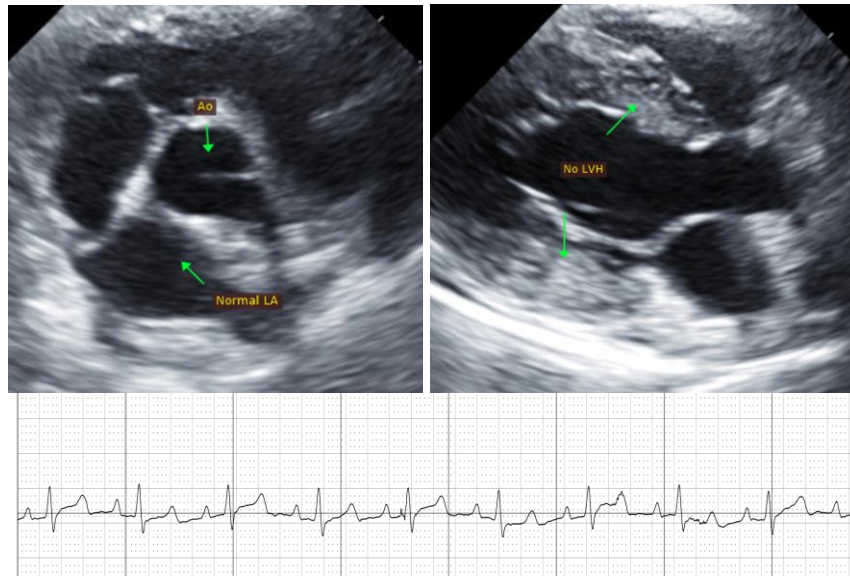
Given these findings, no medications are indicated.

These findings would suggest CHF is not the cause of current or prior labored breathing. Intolerance of steroids is possibility; however, typically in those cases some degree of atrial dilation is noted on echo (not appreciated here). Other possibilities should be considered in this case. I suspect pericardial effusion was present initially, to explain the cardiomegaly so the development of pleural effusion may have been simply progression of the underlying disease. Further systemic evaluation, including fluid sampling if possible, complete abdominal ultrasound and full lab work is recommended.

Anesthetic risk is considered mild. With remodeling and diastolic stiffening, there is an elevated risk for fluid overload in this patient and judicious IV fluid use is recommended. Heart rate stimulating drugs such as atropine, glycopyrrolate or ketamine should be avoided unless medically necessary. Risk for complication with steroid use typically follows LA dilation, which in this case is low. That being said, any cat can experience unexpected signs of intolerance and monitoring of RR/RE is advised particularly in the initiation phase.

Recommend recheck echocardiogram in 1 year to assess for any progressive issues.

IMAGES



The information and recommendations provided are based on the images presented by the referring veterinarian. No evaluation can be communicated regarding pathology that was not visible in the image/video clips provided.

Thank you for this referral. This report was generated using transcription software, and minor dictation errors may be present. If the clinical or image interpretation does not parallel your findings or if I can be of any further assistance, please contact me.

Maggie Machen Lamy, DVM
Diplomate of the American College of Veterinary Internal Medicine (Cardiology)
info@sonopath.com